



Aortic coarctation and associated cardiac lesions – optimal therapeutic approach: report of 2 cases

Koarktacija aorte i pridružene lezije srca – optimalni terapijski pristup

Miloš Velinović*†, Radmila Karan*†‡, Nataša Kovačević-Kostić*†‡,
Biljana Obrenović-Kirčanski*§, Milica Stojimirov||, Vladimir Milićević†,
Dejan Nikolić*||, Dragan Milić*||**

University of Belgrade, *Faculty of Medicine, Belgrade, Serbia; Clinical Center of Serbia, †Cardiac Surgery Clinic, ‡Center for Anesthesiology, §Clinic for Cardiology, ||Clinic for Vascular and Endovascular Surgery, Belgrade, Serbia; University of Niš, ¶Faculty of Medicine, Niš, Serbia; Clinical Center of Niš, ††Clinic for Cardiovascular Surgery, **Clinic for Cardiovascular Surgery, Niš, Serbia

Abstract

Introduction. Aortic coarctation is a congenital condition mostly detected and treated during childhood. Adult patients with coarctation and associated cardiac lesions represent a challenge and a subject of debates concerning adequate treatment. We report 2 patients with aortic coarctation when a surgical treatment was necessary. **Case report.** First patient was a 61-year-old male with previous mechanical aortic valve implantation. He underwent one stage surgical reconstruction of aortic coarctation and surgical repair of aneurysm of ascending aorta. The second patient was a 49-year-old female with aortic aneurysm, bicuspid aortic valve, severe aortic insufficiency and coarctation of aorta below branching of subclavian artery. She underwent the Bentall procedure and surgical repair of coarctation by bypass where the proximal anastomosis was made between the

terminal part of Dacron graft and the lateral part of graft used for Bentall, while the distal anastomosis was made between the terminal part of Dacron graft and the lateral part of descending aorta below coarctation. The postoperative course and the follow-up of the patients of 3 and 1 year, respectively, were without complications. **Conclusion.** Single operation is a better choice in the patients with concomitant pathology such as the aortic aneurysm, or aortic valve disease. Each patient should be analyzed on a single basis, and a decision about a surgical technique and surgical course brought accordingly.

Key words:

aortic aneurysm; aortic coarctation; aortic valve insufficiency; echocardiography; cardiac surgical procedures; treatment outcome.

Apstrakt

Uvod. Koarktacija aorte je kongenitalno stanje koje se najčešće otkriva i leči u detinjstvu. Odrasli bolesnici sa koarktacijom i pridruženim srčanim oboljenjima predstavljaju pravi izazov i temu za stručne polemike oko adekvatnog načina lečenja. Prikazana su dva bolesnika sa koarktacijom aorte kod kojih je hirurški tretman bio neophodan. **Prikaz bolesnika.** Prvi bolesnik bio je muškarac star 61 godinu sa prethodno ugrađenom mehaničkom aortnom valvulom. U jednom aktu je urađena rekonstrukcija koarktacije aorte i operativno zbrinjavanje aneurizme ascendentne aorte. Drugi bolesnik bila je 49-godišnja žena sa aneurizmom aorte, bikuspidnom aortnom valvulom, teškom aortnom insuficijenci-

jom i koarktacijom aorte ispod odvajanja arterije supklavije. Urađena je Bentall operacija i operacija bajpasa između ascendentne i torakalne aorte. Kod oba bolesnika je postoperativni tok protekao bez komplikacija. U periodu praćenja od 1 i 3 godine nije bilo komplikacija. **Zaključak.** Operacija u jednom aktu je bolji izbor kod bolesnika sa pridruženom patologijom kao što je aneurizma aorte i bolest aortne valvule. Svakog bolesnika treba pojedinačno razmotriti i doneti odluku o najpogodnijoj hirurškoj intervenciji.

Ključne reči:

aorta, aneurizma; aorta, koarktacija; zalistak, aortni, insuficijencija; ehokardiografija; hirurgija, kardijalna, procedure; lečenje, ishod.

Introduction

Aortic coarctation is a congenital condition mostly detected and treated during childhood. A diagnosis of coarctation in adulthood is usually incidental one, made during the diagnostic evaluation for other cardiac conditions^{1,2}. The adult patients with coarctation and associated cardiac lesions represent a challenge even in the era of percutaneous stent procedures, and are the subject of many professional debates concerning the most adequate treatment³. Based on the underlying morphology, the age of patient, and presence or absence of other lesions, multidisciplinary team of surgeons, a cardiologist, interventionists and an anesthesiologist should decide on the right course of treatment.

We presented 2 patients with aortic coarctation when the surgical treatment was necessary.

Case report

Case 1

A 61-year-old male was admitted to our hospital for surgical reconstruction of aortic coarctation and aneurysm of ascending aorta. Four years before that, he underwent the surgery to implant the mechanical aortic valve due to the aortic valve insufficiency. This previous aortic valve replacement surgery was not performed in our Clinic and no prior documentation was available to us. We have no knowledge if the diagnosis of coarctation was established then and, if yes, why it was not treated during the aortic valve replacement surgery. Transthoracic echocardiography (TTE) showed the aneurysmatic dilatation of ascending aorta at bulbus level 74 mm. Mitral valve regurgitation of 1-2+/4 was present into the enlarged (50 mm) left atrium. The left ventricle was normal with the preserved systolic function. The artificial aortic valve showed the normal excursions with 1+/4 transvalvular regurgitation. The right ventricle was normal with tricuspid regurgitation of 1+/4 into the dilated right atrium and the right ventricular systolic pressure (RVSP) 31 mmHg. Multislice computed tomography (MSCT) with aortography showed the aneurysmatic dilatation of aortic root and the ascending aorta with the lumen diameter at the level of aortic bulbus 74 × 73 mm, aortic arch 50 × 49 mm as well as a spindle like narrowing of aorta after the branching of left subclavian artery with poststenotic dilatation of the descending aorta (Figure 1). It was not possible to perform coronary angiography due to an extreme dilatation of the ascending aorta. Comorbidities included the arterial hypertension, paroxysmal atrial fibrillation. The patient underwent a repair of aneurysm by interposition of Dacron graft as well as a repair of coarctation by the bypass ascending aorta to the descending aorta with Dacron graft. The approach to the femoral artery cannulation was achieved by establishing the retrograde cardiac pulmonary bypass. Being that it was a cardiac surgery requiring resternotomy (REDO) surgery, adhesiolysis was performed, after which the aorta was cannulated and subsequently clamped. A resection of the aneurysm was performed. The Dacron graft 30 mm was implanted – the prox-

imal anastomosis was sutured to the previously implanted aortic valve, the coronary arteries ostia were detached and re-implanted on the graft. The posterior pericardium was then cut-opened, the posterior side of pericardium was cut-opened and the descending aorta was accessed and clamped distally as well as proximally. After the clamping of the aorta, the Dacron graft 12 mm was sutured terminal-laterally to the descending aorta, followed by the terminal lateral anastomosis between the 12 mm Dacron graft and Dacron graft at the position of the ascending aorta (Figure 2). The graft that was used to treat coarctation was positioned from the ascending aorta graft to the thoracic aorta on the left side. In this case, the approach of positioning the graft behind the vena cava was not used, being that this was a REDO surgery and the numerous adhesions made it technically impossible. The postoperative course and the follow-up of 36 months were without complications.

Case 2

A 49-year-old female, with a history of arterial hypertension and hyperlipidemia, was admitted for a surgical repair of the aortic aneurysm and coarctation of the aorta. Two months prior the surgery, the patient felt heart pounding, and later, the same day, the chest pain propagating to the left upper arm. The intensity of pain was 6/10, and it lasted for two hours. She was admitted to the regional hospital for the evaluation, and a few days later, the patient was transferred to the Emergency Department at our Clinical Center under the suspicion of possible aortic dissection or myocardial infarction. Performed aortography showed the ascending aortic aneurysm, circulatory diameter of around 70 mm and 150 mm length, aortic regurgitation 3+/4. Coronary angiography was not possible due to the unachievable coronary cannulation. Coarctation of the aorta was also visualized. TTE showed the dilated aorta root 39 mm, ascending part 66 mm, aortic arch 46 mm. The descending, thoracic and abdominal aorta were of normal size. Stenosis (coarctation) was evident just below the branching of subclavian artery. The aortic valve was bicuspid and aortic regurgitation of 3+/4 was present. The left ventricle diastolic diameter was enlarged (63 mm). There was hypokinesia of a small part of basal segment of inferior wall, but the global left ventricle ejection fraction was preserved (70%). The structure resembling the intimal flap was visualized in the initial part of ascending aorta. MSCT angiography of the thoracic and abdominal aorta and iliac artery revealed the dilated ascending aorta diameter of 70 mm. Coarctation with internal kinking was spotted at the beginning of descending aorta. There were no signs of dissection. The patient underwent the Bentall surgical procedure and the reparation of coarctation by suturing the terminal part of 10 mm Dacron graft with the lateral part of the Dacron graft that was used for the Bentall procedure. Other part of 10 mm Dacron graft was sutured to the lateral part of descending aorta below coarctation. In this case, there was no need for a Dacron graft of diameter greater than 10 mm, because the patient did not have the classical symptoms for coarctation and she developed collateral circulation.

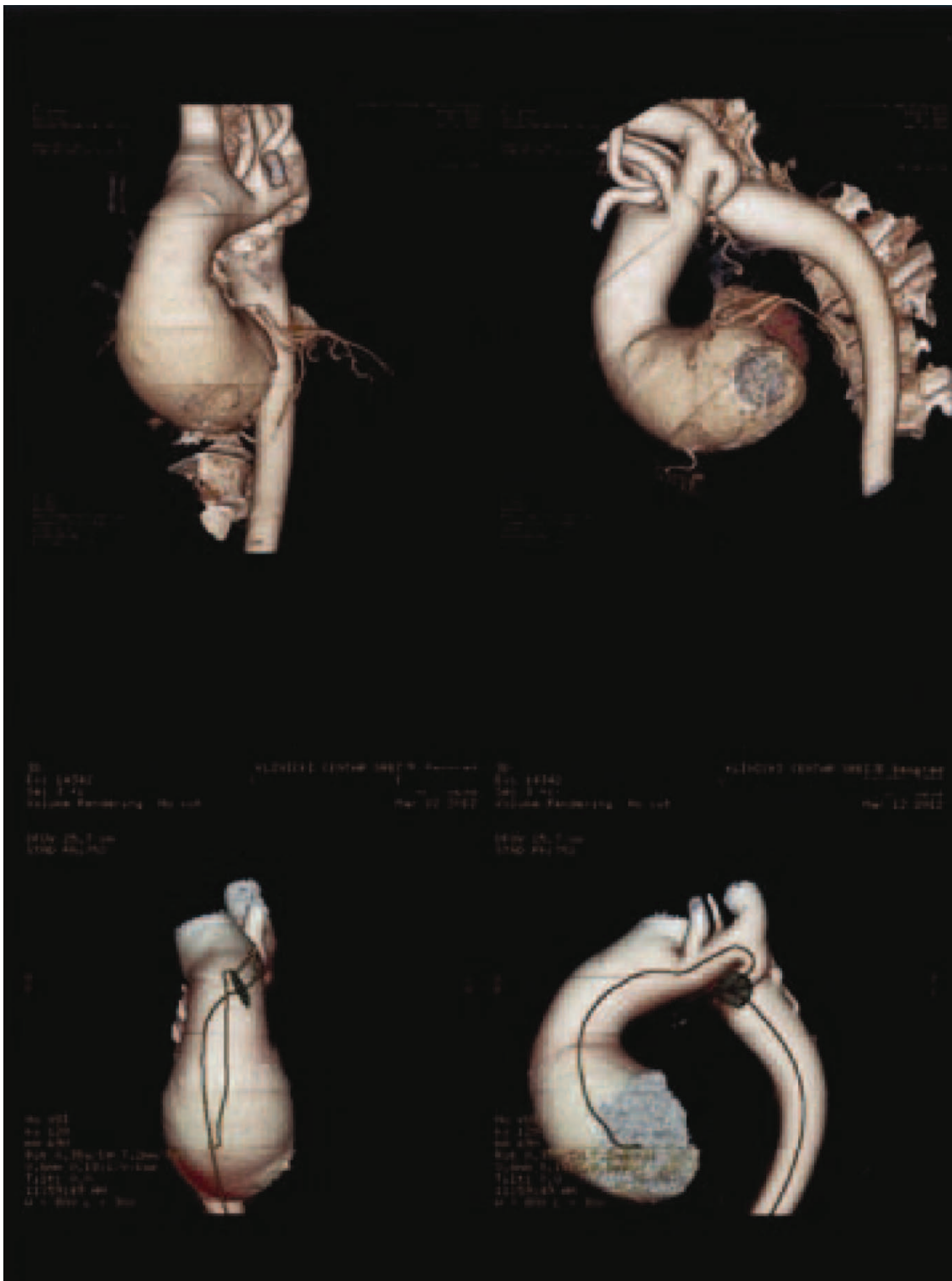

Fig. 1 – Presurgical multislice computed tomography showing aneurysmatic dilatation of aortic root and ascending aorta. A spindle like narrowing of aorta after the branching of left subclavian artery with poststenotic dilatation of the descending aorta. Visible mechanical aortic valve.

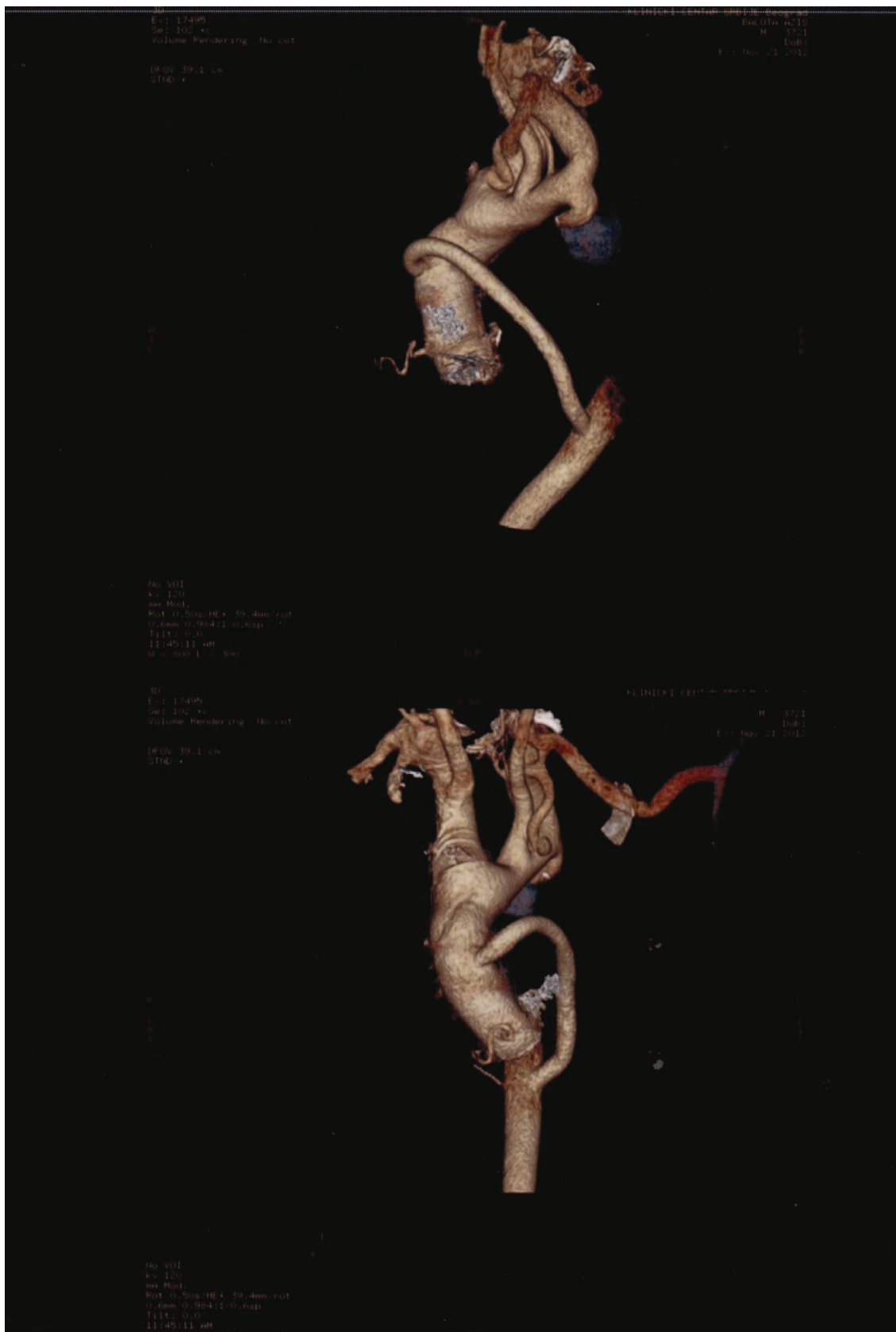


Fig. 2 – Postsurgical multislice computed tomography showing repaired aneurysm with interposition of Dacron graft. Repaired coarctation with extraanatomic bypass (ascending to descending aorta).

Also, the anastomosis was sutured below coarctation enabling the partial native blood flow through coarctation itself. The postoperative pressure gradient in the descending aorta below coarctation was 10 mmHg. The patient was discharged with no postoperative complications. During the period of one-year follow-up, she was without complications.

Discussion

Surgery as a treatment of coarctation of the aorta still has its place, even today in the era of percutaneous procedures. The surgical management of coarctation of the aorta presents technical controversy, especially if other cardiac pathology is involved as well. There is an ever-present question about the choice of the right technique, single-stage or two stage procedure, and which pathology to repair first³.

The advantages of a single stage approach are: a number of surgical procedures and shorter duration of hospitalization. Many authors do not prefer this approach due to its negative side, which includes the hemodynamic instability and myocardial hypoperfusion due to a sudden decrease in afterload⁴. Also, a single stage procedure with one large incision is not preferred because the exposure is poor and there is an increased risk of bleeding. A single stage operation with sternotomy and thoracotomy simultaneously may increase the postoperative pain and risk of atelectasis⁵. The surgical repair of coarctation carries a risk of spinal cord ischemia and consequent paralysis^{6,7}. The lung compression, chylothorax, uncontrollable bleeding, phrenic nerve and laryngeal nerve injury may also occur^{7,8}.

We think that the modified a single stage approach with the extra anatomic bypass technique (ascending to descending bypass) has advantage because the pericardial approach decreases a risk of the above mentioned complications. The use of partial aortic cross clamp allows perfusion distally, decreases possibility of mesenteric ischemia, spinal cord ischemia and consequent paralysis especially in the older patients. Some authors find this to be the technique of choice for the adult patients with the ascending aortic aneurysm, aortic valve or coronary disease associated with coarctation^{7,9,10}.

Even though repairing coarctation in the first stage facilitates the blood pressure control and decreases afterload, a substantial risk of aneurysm rupture still remains between two stage approach operations. A single stage procedure is preferred in these patients³. The two-stage procedure includes the correction of coarctation and associated cardiac lesion⁴. There is an ongoing debate about which pathology should be corrected first. Repairing coarctation in the first stage allows the relief of proximal hypertension and safer aortic cannulation for the second stage procedure¹¹. Operating on first the cardiac lesions enables the coronary and myocardial flow redistribution and prevents left ventricular ischemia caused by sudden decrease in afterload. Of course, each approach carries its disadvantages as well. The patients whose cardiac lesions are repaired in the first stage have a risk of bleeding and hemodynamic instability due to the increase in the afterload, as well as occurrence of atrial fibrillation and ischemia in the dilated left ventricle. Anticoagulation and renal perfusion complications may occur^{3,12}.

If aortic dissection of ascending aorta occurs in a patient with coarctation, it is rational to manage surgically the more urgent problem, either to repair the ascending aorta first, then repair coarctation in a single stage using one incision, or two incisions (median sternotomy and thoracotomy), which is a great trauma for the patient. All patients treated for aortic coarctation should have regular follow-ups, because of the significant incidence of recoarctation, aneurysm, stenosis or incompetence of aortic valve, and coronary artery disease¹³.

Conclusion

The choice of surgical technique depends on skills and experience of a surgical team, and the surgical equipment as well. Single operation is a better choice for the patients with concomitant pathology such as the aortic aneurysm, or the aortic valve disease. Each case should be analyzed on a single basis and decision about the surgical technique and surgical course brought accordingly.

REFERENCES

1. *Koletsis E, Ekonomidis S, Panagopoulos N, Tsaousis G, Crockett J, Panagiotou M.* Two stage hybrid approach for complex aortic coarctation repair. *J Cardiothorac Surg* 2009; 4: 10.
2. *Maron BJ, Humphries JO, Rowe RD, Mellits ED.* Prognosis of Surgically Corrected Coarctation of the Aorta: A 20-Year Postoperative Appraisal. *Circulation* 1973; 47(1): 119–26.
3. *Ugur M, Alp I, Arslan G, Temizkan V, Ucak A, Yilmaz AT.* Four different strategies for repair of aortic coarctation accompanied by cardiac lesions. *Interactive Interact Cardiovasc Thorac Surg* 2013; 17(3): 467–71.
4. *Mulay AV, Asbraf S, Watterson KG.* Two-Stage Repair of Adult Coarctation of the Aorta With Congenital Valvular Lesions. *Ann Thorac Surg* 1997; 64(5): 1309–11.
5. *Horai T, Shimokawa T, Takeuchi S, Okita Y, Takasashi S.* Single-Stage Surgical Repair of Type II Acute Aortic Dissection Associated With Coarctation of the Aorta. *Ann Thorac Surg* 2007; 83(3): 1174–5.
6. *Korkmaz AA, Guden M, Onan B, Tarakci SI, Demir AS, Sagbas E, et al.* New technique for single-staged repair of aortic coarctation and coexisting cardiac disorder. *Tex Heart Inst J* 2011; 38(4): 404–8.
7. *Connolly HM, Schaff HV, Izhar U, Dearani JA, Warnes CA, Orszulak TA.* Posterior pericardial ascending-to-descending aortic bypass: an alternative surgical approach for complex coarctation of the aorta. *Circulation* 2001;104(12 Suppl 1): 133–7.
8. *Sun LZ, Luo XJ, Liu YM.* Single-stage treatment of aortic coarctation and aortic valve disease. *Asian Cardiovasc Thorac Ann* 2003; 11(3): 208–12.
9. *Ramnarine I.* Role of surgery in the management of the adult patient with coarctation of the aorta. *Postgrad Med J* 2005; 81(954): 243–7.
10. *Wu Q, Chen X, Li H, Wang L, Xue H.* Ascending-to-descending aortic bypass via posterior pericardium for complex coarctation of aorta. *J Card Surg* 2009; 24(2): 167–9.

10. *Rufilanchas JJ, Villagra F, Maroñas JM, Tellez G, Agosti J, Juffe A*, et al. Coarctation of the aorta and severe aortic insufficiency: What to repair first? *Am J Surg* 1977; 134(3): 428–30.
11. *Morris RJ, Samuels LE, Brockman SK*. Total simultaneous repair of coarctation and intracardiac pathology in adult patients. *Ann Thorac Surg* 1998; 65(6): 1698–702.
12. *Celermajer DS, Greaves K*. Survivors of coarctation repair: fixed but not cured. *Heart* 2002; 88(2): 113–4.
13. *Celermajer DS, Greaves K*. Survivors of coarctation repair: fixed but not cured. *Heart* 2002; 88(2): 113–4.

Received on October 18, 2017.

Revised on January 16, 2018.

Accepted on January 17, 2018.

Online First January, 2018.